

PATIENT PRESENTING CLINICAL SIGNS

Roxy Nunez Organomegaly on palp. possible mass effect on lat abd rad

ULTRASONOGRAPHIC EXAMINATION OF THE ABDOMEN

SPECIES

Canine

Urinary System

The urinary bladder, trigone, cystourethral junction, and visible pelvic urethra to a depth of 2 cm exhibited normal thickness and tone. Anechoic urine was present in the lumen with no evidence of urine/lumen sediment, mineral, or calculi. The ureteral papillae were normal. The ureters were not visible which is normal. No evidence of inflammatory or neoplastic changes was noted.

BREED

Pitbull

SEX

FS

Normal size and margination were present in the kidneys. A normal 1:3 cortex / medulla ratio was maintained. The medulla and cortices were uniform in texture with some increased echogenicity and mild loss of corticomedullary symmetry and definition expected for the age of the patient. No evidence of pelvic dilation was present. The left kidney measured 6.3 cm in length. The right kidney measured 6.6 cm in length.

AGE

10yr

The area of the iliac trifurcation was free of pathology including no evidence of medial iliac or sublumbar lymphadenopathy or masses.

Adrenal Glands

WEIGHT

64.9lb

The left adrenal gland was uniform in size and contour with a uniformly hypoechoic parenchyma. The left adrenal gland measured 0.56 cm width at the caudal pole.

A non-homogeneous mildly expansive hyperechoic nodule was present in the cranial right adrenal gland with mild associated symmetrical capsule expansion. The nodule did not exhibit signs of mineralization or vascular invasion. The nodule measured 1.7 cm x 1.3 cm. The right adrenal gland measured 0.57 cm width at the caudal pole.

INTERPRETED BY

R. McKenzie Daniel,
DVM, DABVP
(Canine and Feline)

Spleen

The spleen exhibited possible mild caudal folding with a finely textured and homogenous parenchyma which was hyperechoic to the liver and renal cortical parenchyma. The capsule was smooth and regular without apparent expansion. The splenic vasculature at the hilus was normal in volume with no evidence of congestion or thrombosis. Acute to chronic inflammatory, neoplastic, or benign parenchyma changes were not noted.

IMAGING PERFORMED BY

Rebecca Hamilton

HOSPITAL NAME

Wantage Veterinary
Hospital

Liver/Gallbladder

The liver was subjectively normal in size, structure, and contour. The liver parenchyma was mildly nonuniform and hypoechoic to the spleen with a moderate coarse echotexture and subjective mild to benign parenchymal remodeling. The hepatic and portal vasculature were normal in appearance without signs of congestion. The gallbladder was non-distended in size with thin walls and primarily anechoic luminal content. The cystic and common bile ducts were normal.

REFERRING VET

Dr Bullock

Gastrointestinal

INVOICE 24123

The stomach presented intact wall layering with a normal wall layer ratio. The lumen of the stomach was empty with no signs of ileus, obstruction or foreign material.

DATE

03/05/2026



PATIENT

Roxy Nunez

The small intestine presented intact wall layering with 1:3 muscularis/mucosa ratio. The lumen of the small intestine was empty with no signs of mechanical/metabolic ileus, obstruction or foreign material. Normal visible colon wall layers were present with apparent formed feces in lumen.

SPECIES

Canine

Pancreas

The parenchyma of the left limb, body and right limb of the pancreas presented isoechoic to the adjacent omental fat. A normal curvilinear capsule contour of the pancreas was present. The visible pancreatic duct was normal. No signs of active inflammation or neoplastic disease was evident.

BREED

Pitbull

Free Abdomen

No peritoneal effusion was present.

SEX

FS

No omental masses.

No visualized significant or swollen lymphadenopathy.

ULTRASONOGRAPHIC FINDINGS

AGE

10yr

Primary

- Normal possible mild folded spleen.
- Normal liver size exhibiting mild parenchymal remodeling.
- Age related renal changes.
- Right adrenal nodule- hyperplasia, adenoma, emerging right adrenal tumor possible.

WEIGHT

64.9lb

INTERPRETATION OF THE FINDINGS & FURTHER RECOMMENDATIONS

INTERPRETED BY

R. McKenzie Daniel,
DVM, DABVP
(Canine and Feline)

No evidence of intra-abdominal primarily hepatic or splenic mass. Potential mild splenic folding given impression of mass on radiographs possible. The possible mild splenic folding not indicative of splenic pathology.

IMAGING PERFORMED BY

Rebecca Hamilton

Adrenal screening could be considered if clinical signs consistent with Cushing syndrome are present given right adrenal nodule. The liver was not overtly consistent with steroid hepatopathy criteria. Monitoring of systemic BP for evidence of hypertension, which may allude to emerging right pheochromocytoma is recommended. If hypertension is documented, a urine metanephrine level is suggested.

HOSPITAL NAME

Wantage Veterinary
Hospital

Serial sonographic monitoring of the right adrenal nodule for evidence of progression with initial recheck in 4-6 weeks is recommended.

REFERRING VET

Dr Bullock

INVOICE
24123

DATE
03/05/2026



PATIENT

Roxy Nunez

SPECIES

Canine

BREED

Pitbull

SEX

FS

AGE

10yr

WEIGHT

64.9lb

INTERPRETED BY

R. McKenzie Daniel, DVM, DABVP
 (Canine and Feline)

IMAGING PERFORMED BY

Rebecca Hamilton

HOSPITAL NAME

Wantage Veterinary Hospital

REFERRING VET

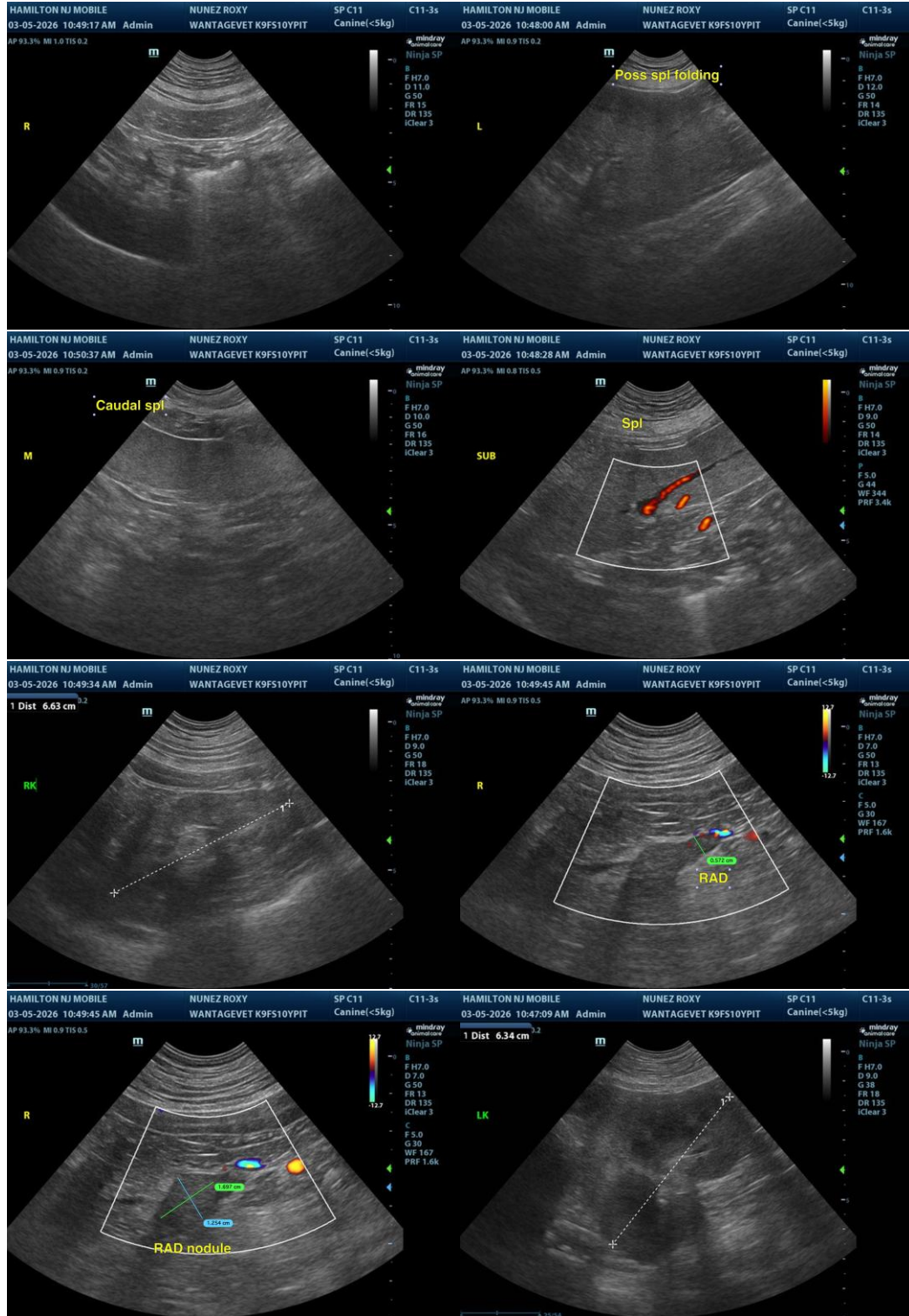
Dr Bullock

INVOICE

24123

DATE

03/05/2026





PATIENT

Roxy Nunez

SPECIES

Canine

BREED

Pitbull

SEX

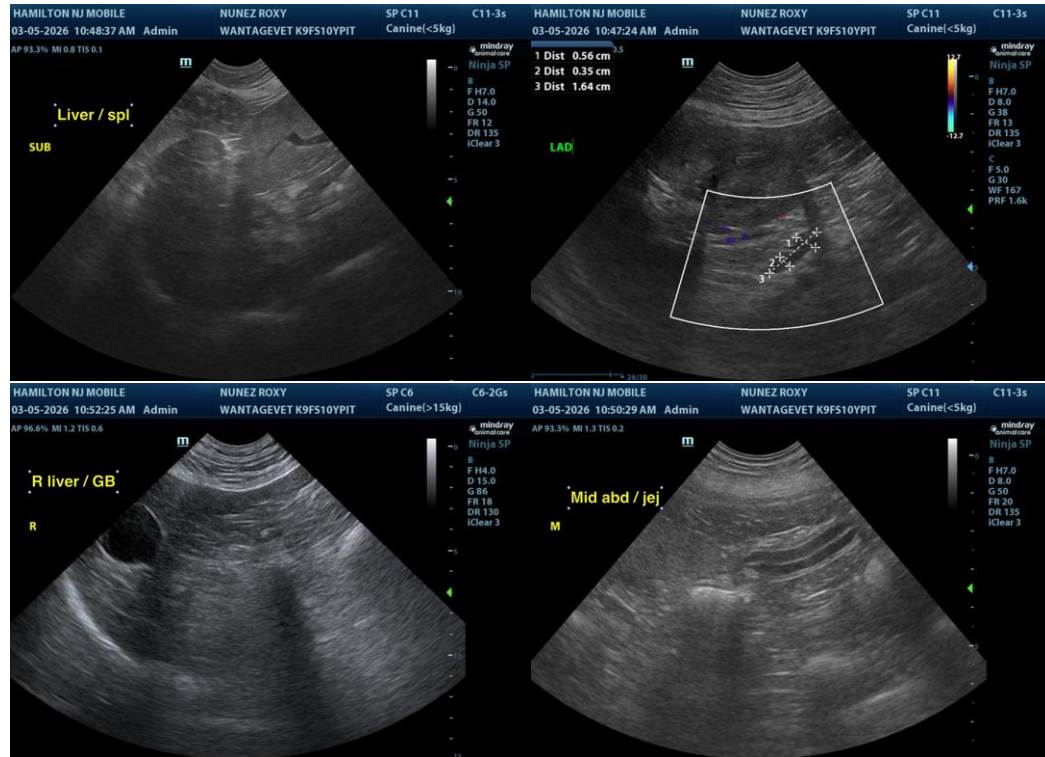
FS

AGE

10yr

WEIGHT

64.9lb



The information and recommendations provided are based on the images presented by the referring veterinarian/sonographer. No evaluation can be communicated regarding pathology that was not visible in the image/video clips provided.

INTERPRETED BY

R. McKenzie Daniel, DVM, DABVP (Canine and Feline)

Thank you for this referral. If the clinical or image interpretation does not parallel your findings or if I can be of any further assistance, please contact me.

IMAGING PERFORMED BY

Rebecca Hamilton

R. McKenzie Daniel, DVM, DABVP (Canine/Feline Practice)
info@sonopath.com

HOSPITAL NAME

Wantage Veterinary Hospital

REFERRING VET

Dr Bullock

INVOICE
24123

DATE
03/05/2026